

Focused Review: Current Trends in Platelet-Rich Plasma Injection Treatments

Adam D. Weglein¹

Abstract: Platelet-Rich Plasma (PRP) is a newly developed treatment that can lead to enhanced tissue healing of many structures in Orthopedic Medicine. This focused review explores the current use of PRP, and discusses its future directions and applications.

Keywords: Platelet-Rich Plasma, pain, osteoarthritis, non-surgical orthopedic treatment

INTRODUCTION

Platelet-Rich Plasma (PRP) is a treatment to improve tissue repair using a patient's own platelet-derived growth factors. The application of these growth-factor-rich platelets helps augment healing in tissues such as tendons, ligaments, and intra-articular synovial joints [1]. The procedure involves a venopuncture, which is placed in a semi-automatic centrifugation-filtration system to separate out the platelet-rich component [1]. This can be performed in an outpatient clinic setting or the operating room. With the use of a wide range of commercially available kits and centrifugation systems, a PRP graft can be synthesized. Although these may be injected blindly, or with traditional fluoroscopy, ultrasound has gained favor recently. Ultrasonography has the advantage of insuring the PRP product is placed directly in the site of suspected pathology (e.g. ligament tear) with real time needle guidance and tissue visualization without radiation [1] (Fig. 1).

Ferrari first promoted the use of PRP in cardiac surgery and the treatment of cutaneous ulcers [2, 3]. PRP has since been applied in many areas of medicine including: orthopedics, podiatry, otolaryngology, neurosurgery, dentistry, wound healing, and in preventing post-operative blood loss [4].

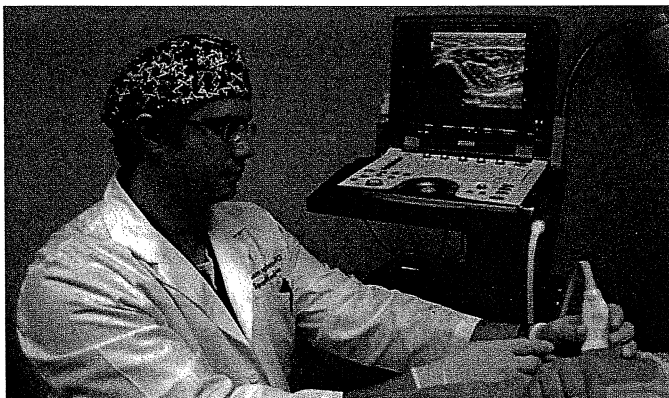


Figure 1. Dr. Weglein demonstrating ultrasound guided PRP.

PLATELETS AND HEALING

Blood is composed of red blood cells, white blood cells, and platelets. Platelets are made in the bone marrow, have a circulating half-life of 7-10 days, and are important for the hemostasis of clotting, which initiates the normal tissue healing process [5]. Within clots, activated platelets secrete pro-aggregation factors such as serotonin, calcium, and adenosine diphosphate (ADP). ADP is a nucleotide that binds to platelet receptors leading to further platelet activation [6]. These activated platelets are responsible for the three stages of tissue healing: inflammation, proliferation and remodeling [4]. These factors in turn cause the release of growth factors, cytokines, chemokines, and adhesion proteins necessary for angiogenesis and extra-cellular matrix formation including: Transforming Growth Factor β (TGF- β); Epithelial Growth Factor (EGF); Vascular Endothelial Growth Factors (VEGFs); Platelet-Derived Growth Factor (PDGF); and Fibroblast Growth Factors (FGFs) [7, 8]. With the use of a centrifuge, PRP concentrates and separates these growth-factor-rich platelets from whole blood. These platelets are then re-injected to help augment natural tissue healing [4].

RESEARCH AND CLINICAL USE OF PRP

The recent expansion in the use of PRP has led to a number of clinical studies. Specifically, PRP has already shown promise in the treatment of knee osteoarthritis, tennis elbow-lateral epicondylitis, and plantar fasciitis [1, 9]. There are also a number of emerging applications in the treatment of cartilaginous, spinal, ligament and tendon, and cutaneous nerve disease states [8, 10-12].

Address correspondence to: Adam D. Weglein, D.O., 3838 North Braeswood Blvd, #177, Houston, TX 77025. Email: awglein2002@yahoo.com.

¹ Center for Spine Sports and Physical Medicine, Tomball, TX, USA

CARTILAGINOUS APPLICATION

PRP has been shown to increase femoral cartilage growth [1]. Additionally, PRP outperformed hyaluronic acid injections in mild and advanced knee osteoarthritis. In this study 150 patients were enrolled. Fifty received a series of three PRP injections, 50 received a series of three high molecular weight hyaluronic acid injections, and the remaining 50 received a series of three low-molecular weight hyaluronic acid injections. At 6 months, the PRP group demonstrated greater efficacy than both hyaluronic acid groups in reducing pain, symptoms and recovering articular function [13, 14].

SPINAL APPLICATION

Spinal PRP research has had mixed results and has focused on spinal fusion and disc health [12, 15]. One study found PRP plus allograft equal, in radiographic and clinical outcomes, to autograft in one or two inter-body fusion with supplemental posterior fixation. This is significant in that it may eliminate morbidity associated with iliac crest graft harvesting [15]. The basic science research has focused on the physiologic healing responses to disc injury. PRP has shown a mild stimulatory effect on intervertebral disc cells [12]. Specifically, PRP treatment stimulated cell proliferation and significantly increased proteoglycan and collagen synthesis [15]. PRP induced synthesis was greater in the nucleus pulposus cells than in the annular cells [15].

Dr. Danielle Aufiero has recently commented in a personal email to the author on her successful use of PRP in the treatment of cervical, thoracic, and lumbar facet pain. Her use of ultrasound guided facet PRP injections is based on the patient having inconclusive results with prolotherapy or corticosteroid under fluoroscopic guidance. Positive predictors of successful facet PRP include: isolated facet mediated pain with radiologic diagnosis of facet arthropathy; isolated pain that is temporarily relieved with chiropractic adjustments; and a positive diagnostic intra-articular local anesthetic and corticosteroid injection. Negative predictors include significant degenerative disc disease; history of spine surgery; and grade 3-4 spondylolisthesis. Of the patients who underwent PRP facet injection, 65-70% had a greater than 50% pain reduction and did not have to go onto to medial branch block or radiofrequency. This information is very recent and pending publication at this time.

LIGAMENT AND TENDON APPLICATION

PRP has been shown to be effective in the treatment of chronic elbow ligament and tendon dysfunction [9]. This has led to the authors application of PRP to other ligaments including the iliolumbar, posterior sacroiliac, sacrospinous, sacrotuberus, and interspinous. Here in

the cases of capsular pain, a good physical exam (Hackett-Hemwall ligament pain referral patterns) followed by ultrasound-guided injection of PRP may provide both diagnostic clarification as well as therapeutic benefit [16]. In this and the author's experience, positive predictors of success include pain or laxity over the ligaments along with positive provocative maneuvers (e.g. FABER test for SI joint dysfunction, etc). Traditional intra-articular fluoroscopic blockade may also be enhanced with PRP ligament injection.

CUTANEOUS NERVE APPLICATION

Neurogenic inflammation has been described previously [17, 18]. Neurogenic inflammation can occur clinically in patients with refractory pain over the posterior superior iliac spine (PSIS) after spinal fusion. Here cutaneous nerves become inflamed leading to a neuropathic pain state [18-21]. PRP application to these damaged cutaneous nerves has been considered in light of recent descriptions of PRP induced nerve regeneration [10, 11, 19, 21-23]. Subsequently, this author has considered simultaneous PRP injection into the SI joint and ligaments, as well as the cluneal nerves.

PRODUCT SAFETY

Given the autologous nature of PRP, blood borne infections (e.g. HIV) are not relevant as a source of concern. In fact, there is even some antimicrobial activity reported against *Staphylococcus aureus* [24].

CONCLUSION

Platelet-Rich Plasma (PRP) improves tissue repair using the growth factors present on the patient's own platelets. The application of these growth-factor-rich platelets helps augment healing in tissues such as tendons, ligaments, discs, and intra-articular synovial joints. Although anecdotal outcomes have been promising, level one studies are clearly needed to elucidate the exact number of PRP treatments, the volume of PRP needed to inject, and the time frame between injections for current applications. Furthermore, there is a need to evaluate the potential synergistic effects on growth hormones and bone marrow stem cells. A clearer understanding of the role of PRP in mediating neurogenic inflammation will lead to expanded indications for orthobiologic use.

ACKNOWLEDGEMENT AND AUTHORSHIP STATEMENT

Dr. Weglein designed, authored, submitted, and approved the final manuscript. There was no funding received for this manuscript or other disclosures or conflicts to report.

REFERENCES

1. Sampson S, Reed Marty, Silvers H, Meng M, Mandelbaum B. Injection of Platelet-Rich Plasma in Patients with Primary and Secondary Knee Osteoarthritis: A Pilot Study. *The American Journal of Physical Medicine & Rehabilitation*. Dec 2010;961-969.
2. Ferrari M, Zia S, Valbonesi M, Henriquet F, et al. A New technique for hemodilution, preparation of autologous platelet-rich plasma and intraoperative blood salvage in cardiac surgery. *Int J Artif Org*. 1987; 10:47-50.
3. Margolis DJ, Kantor J, Santanna J, et al. Effectiveness of platelet releasate for the treatment of diabetic neuropathic foot ulcers. *Diabetes Care*. 2001; 24(3): 483-488.
4. Sampson S, Gerhardt M, Mandelbaum B. Platelet rich plasma injection grafts for musculoskeletal injuries: A review. *Curr Rev Musculoskelet Med* 2008; 1:165-74.
5. Akeda K, An H.S, Okuma M. et al. Platelet-rich plasma stimulates porcine articular chondrocyte proliferation and matrix biosynthesis. *Osteoarthritis and cartilage*. 2006;14:1272-1280.
6. Murugappa S, Kunapuli SP. The role of ADP receptors in platelet function. *Front Biosci*. 2006, 11:1977-86.
7. Kevy SV, and Jacobson MS. Comparison of methods for point of care preparation of autologous platelet gel. *J Extra Corpor Technol*. 2004; 36: 28-35.
8. Mei-Dan O, Lippi G, Sanchez M, Andia I, Maffulli N. Autologous Platelet-Rich Plasma: A revolution in soft tissue sports injury management. *The Physician and sports medicine*: 2010, vol 38:4.
9. Mishra A, Pavelko T. Treatment of Chronic Elbow Tendinosis with Buffered Platelet-Rich Plasma. *American Journal of Sports Medicine*; 2006;5(3).
10. Ding XG, Li SW, Zheng XM, et al. The affect of Platelet-Rich Plasma on cavernous nerve regeneration in a rat model. *Asian J Androl*. March 2009;11(2): 215-221.
11. Farrag Ty, Lehar M, Verhaegen P et al. effect of platelet rich plasma and fibrin sealant on facial nerve regeneration in a rat model. *Laryngoscope* Jan 2007;117(1): 157-65.
12. Akeda K, An H, Pichika R et al. Platelet-Rich Plasma (PRP) Stimulates the Extracellular Matrix Metabolism of Porcine Nucleus Propulsos and Annulus Fibrosis Cells Cultured in Alginate Beads, *Spine* 2006; 9:959-966.
13. Kon E, Buda R, and Filardo G, et al. Platelet Rich plasma: intra-articular knee injections produced favorable results on degenerative cartilage lesions. *Knee Surg sports tramatol arthroscop* April 2010: 4.
14. Kon E, Buda R, Mandelbaum N, Filardo G et al. PRP intra-articular injection versus visco supplementation as treatments for early osteoarthritis. Podium Presentation No: 685. *Am Acad Ortho Surgeons*, New Orleans March 12, 2010.
15. Jenis L, Banco R, Kwon B. A prospective study of autologous growth factors (AGF) in lumbar interbody fusion. *The Spine Journal*. 2006; 6:14-20.
16. Hackett G, Hemwall G. Ligament and tendon relaxation treated by prolotherapy. 5th edition, Hackett Hemwall Foundation publisher. 2008:27-36.
17. Geppetti Pertangelo, Holzer P. Neurogenic Inflammation. Edited CRC Press 1996: 33-43.
18. Jancso G, Berczi I, et al. Neurogenic inflammation in health and disease. *Neuroimmune Biology*, Volume 8: 39-75.
19. Lyftogt JA. Prolotherapy for recalcitrant lumbago. *Aust Musculoskeletal Med* 2008; 13(1): 18-20.
20. Brain SD, and Moore PK. Pain and Neurogenic Inflammation. Birkhauser Verlag 1999: 115-135.
21. Lyftogt J. Subcutaneous prolotherapy treatment of refractory knee, shoulder and lateral elbow pain. *Aust Musculoskeletal Med* 2007; 12(2): 110-12.
22. Elgazzar R, Mutabagani MA, Abdelaal SE, Sadakah AA. Platelet Rich plasma may enhance peripheral nerve regeneration after cyanoarylate teanastomosis: a controlled blind study in rats. *Int J Oral Maxillofac Surg*. 2008 Aug 37(8): 748-55.
23. Chalfoun C.T., Wirth G.A., Evans D. Tissue engineered nerve constructs: where do we stand? *J Cell Mol. Med*. 2006; 10(2): 309-317.
24. Moojen DJ, Everts PA, Schure RM, et al. Antimicrobial activity of platelet-leukocyte gel against *Staphylococcus aureus*. *J Orthop Res*. 2008; 26(3): 404-410.