

# Platelet-rich plasma therapy as a first-line treatment for severe Achilles tendon tear: a case report

Steven Sampson, Danielle Aufiero, Michael Meng, Anthony Bledin, Terry Gillette, Mona Zall

**Background:** This case report evaluates non-surgical ultrasound-guided injection of platelet-rich plasma (PRP) in a sports medicine setting, as a first-line treatment to repair a severely torn Achilles tendon of a 71-year-old male. Diagnosis was made through clinical examination and imaging, and follow-up data was collected at 6 and 24 weeks post-injection.

**Content:** At 6 weeks post-injection, autologous PRP resulted in a substantial reduction of the Achilles torn fibres, with only minor focal tear evident on musculoskeletal ultrasound. At 24 weeks post-injection, the tear was completely resolved on MRI and the patient returned to full functional activity.

**Conclusions:** Currently there is limited data, with mixed results, regarding PRP treatment for Achilles tendinopathy, and limited reports of using PRP in humans within the first few weeks of injury. This case report demonstrates success of early PRP therapy to repair a severe Achilles tendon tear, from both radiological and functional perspectives. However, larger controlled trials using follow up MRI and sonographic imaging are needed to determine if early PRP treatment post tendon injury would be a safe and effective alternative to accelerate healing.

Key words: ■ Achilles tendon tear ■ growth factors ■ injection ■ platelet-rich plasma

Submitted 30 June, sent back for revisions 23 August; accepted for publication following double-blind peer review 19 November 2010

Musculoskeletal injuries are the most common cause of severe long-term pain and physical disability (Woolf and Pfleger, 2003). The Achilles tendon is an area commonly injured as a result of overuse. Initially, conservative measures such as ice, rest, orthotics, and physical therapy are used, with a failure rate of 25% eventually leading to surgery (Mishra, 2009; Chang, 2010). However, patients who undergo surgery have a long recovery period, with increased incidence of complications (Mishra, 2009; Chang, 2010). Cortisone injections directly into the tendon are frequently performed, but are not recommended because of increased incidence of tendon rupture (Sampson et al, 2008).

The last decade has brought about significant advances in musculoskeletal injury repair, including concentrated autologous platelet-rich plasma (PRP) therapy (Everts, 2006; Sampson, 2008). PRP's healing properties result from its ability to release growth factors and chemoattractants, congregating macrophages and fibroblasts to the site of

injury to facilitate tendon repair (Everts et al, 2006) The growth factors found in platelets have been shown to be key in the reparative process of tendons (Sanchez et al, 2007). PRP is typically administered into chronic or subacute tendon tears or tendinosis when conservative measures fail, or at the time of surgery to improve post-operative recovery. This case report demonstrates the use of PRP to potentially accelerate healing in a more acute setting and without having exhausted conservative measures.

At the 2010 Annual American Academy of Orthopaedic Surgeons meeting, preliminary data was presented that demonstrated that 28 out of the 30 patients with Achilles tendinosis who failed 6 months of conservative treatment were able to return to their pre-injury activity levels after a single injection, within several months following PRP therapy, without requiring additional therapy (Leahy, 2010). Moreover, Aspenberg and Virchenko (2004) were able to show that PRP was able to facilitate the repair of a transected Achilles tendon in rats, when administered

**Steven Sampson** is a *Physiatrist, Orthohealing Center, Los Angeles, California*; **Danielle Aufiero** is a *Physiatrist, Orthohealing Center, Los Angeles, California*; **Michael Meng** is a *Sonographer, Orthohealing Center, Los Angeles, California*; **Anthony Bledin** is a *Radiologist, Ocean Medical Imaging, Oxnard, California*; **Terry Gillette** is a *Physical Therapist, Gillette and Associates Physical Therapy, Woodland Hills, California*; and **Mona Zall** is a *Medical Student, Western University of Health Sciences, Pomona, California, USA*

Correspondence to: S Sampson  
E-mail: [drsampson@orthohealing.com](mailto:drsampson@orthohealing.com)

six hours after the initial tear. This is in contrast to published human studies, in which PRP is typically injected at a point of sub-acute or chronic status of Achilles tendinopathy. The rat tendons demonstrated increased callus strength, stiffness and material characteristics. Contrastingly, a recent study by De Vos et al (2010) showed that ultrasound guided PRP, versus normal saline injections followed by eccentric exercises, made no significant difference in the function and pain levels of individuals who had chronic Achilles tendinopathy. However, there were several limitations to their study, including the lack of follow-up after a 6-month period, and the absence of follow-up imaging. Another limitation was that they relied on the tendon collagen, rather than calcium chloride and thrombin, to activate the platelets, which may have caused the spread of the platelets to other regions, decreasing the effectiveness of PRP. Both study groups demonstrated symptomatic improvement, which were attributed to eccentric exercises, although this variable was not isolated as a control. Also, Sanchez et al (2007) showed that patients who received Achilles tendon surgery with PRP had a quicker recovery time than those who only received surgery. The individuals with PRP were able to return back to their sport at 14 weeks, while the ones who only had surgery returned back to their sport at 22 weeks. There is also evidence that suggests that dry needling with autologous blood may stimulate repair in patellar tendons. (James et al, 2007)

There is conflicting data that is emerging regarding Achilles tendonopathies being treated with PRP. This descriptive case report is not only one of the first published reports in the usage of PRP as a first line treatment in an acute setting to facilitate repair for a severe traumatic Achilles tendon tear, but it is also provides documented MRI and sonographic evidence of healing. Severe acute tendon injuries are a common occurrence in the overall population, not just in elite athletes, which necessitates lengthy rehabilitation, activity restrictions, and even surgical repair. The aim of this study was to determine if early PRP could be used successfully as an alternative to conventional therapies to accelerate recovery, which would benefit the general population.

---

### THE PATIENT

---

A 71-year-old male, while playing badminton, heard an audible pop in his right ankle

and experienced an isolated partial Achilles tendon rupture. Initially he was seen by an orthopedic surgeon, who presented him with the option of either surgery or conservative treatment. The patient opted for conservative therapy and was placed in a cast for three and a half weeks, followed by a walking boot, which was poorly tolerated. The patient was then evaluated at the authors' clinic for potential treatment with autologous PRP therapy, as an alternative to traditional conservative treatments. The patient was presented with the traditional non-surgical treatment options, including continued bracing, home eccentric exercise program and physical therapy, acupuncture, and non-steroidal anti-inflammatory drugs. The patient was not satisfied with the inconvenience of immobilization and slow process of healing anticipated with physical therapy. Therefore he elected to undergo PRP therapy in combination with physical therapy, in an effort to facilitate healing and accelerate the recovery time.

---

### METHODS

---

Achilles tendon injury was diagnosed through routine clinical examination and imaging. Ultrasound guided autologous PRP treatment was administered 26 days after the initial injury, followed by physical therapy, which was initiated 5 days after PRP injection. The patient was then followed-up, with both clinical examination and imaging, at 6 and 24 weeks after PRP treatment.

### Pre-injection evaluation

Immediately following the injury, an MRI of the right ankle demonstrated marked tearing of approximately 90% of the Achilles tendon at the musculotendinous junction, with some posterior fibres intact. The deltoid, calcaneofibular, anterior and posterior talofibular ligaments, and posterior tibial and peroneal tendons of the ankle appeared normal. A diagnostic musculoskeletal ultrasound was also performed 26 days after the initial injury, and following discontinuation of the walking boot. The ultrasound showed minimal evidence of healing when compared to the initial MRI, with tendon swelling along with a superficial hypo/anechoic characteristic, and clearly defined intratendinous fluid filled transverse tearing. Additionally, there was a focal hyperechoic area at the deep margin representing poorly organized fusiform, blunt contracted fibres in the distal segment.

Clinically, the patient had severe compromise in his ambulatory potential and activities of daily living, due to pain and weakness of the affected ankle. A physical exam revealed a mildly swollen Achilles tendon, with maximum point tenderness located 2 cm from its calcaneal insertion. The patient was observed to have an antalgic gait.

### Diagnostic imaging sequence

Magnetic Resonance Imaging (MRI) images were acquired on a Hitachi Airis II High Performance open MRI Scanner (Figure 1a-c) at the time of initial injury through the orthopedic clinic. The patient had >90% complete tear of the Achilles tendon, as per the radiologist's MRI report. The first diagnostic musculoskeletal ultrasound was done at 26 days post injury, and after cast removal, to ensure no significant changes had occurred since the MRI (Figure 2) and initial trauma. Ultrasound imaging was performed with a 7.6–13.0 MHz high frequency linear transducer Sonosite Micromaxx, B-mode ultrasound technique. Colour power Doppler application was used for detection of hyperemia. The Patient was also re-imaged by means of ultrasound at 6 weeks (Figure 2) and MRI at 24 weeks post PRP Injection (Figure 1a-c).

### PRP preparation and delivery

PRP was prepared using the Magellan® Autologous Platelet Separator (Arteriocyte Medical Systems, Hopkinton, Massachusetts). A total of 54 cc of autologous blood was drawn into a 60cc syringe (BD), containing 6 cc of ACD-A, and processed to yield a total of 5 cc of PRP (~8.5 X Baseline; manufacturer's internal validation).

The patient was anesthetized locally with 5 cc of 1% lidocaine into the corresponding subcutaneous tissue. Thereafter, the PRP sample was combined with 0.6 cc of CaCl combined with 1cc of bovine thrombin and administered using a 22 g 3.5 in needle into the Achilles tendon, under musculoskeletal ultrasound guidance. Needling of the affected tendon fibres was performed under live ultrasound in colour Doppler mode to ensure proper flow of PRP into the tendon. The patient tolerated the procedure well and without any intra or post-procedure adverse reactions.

### Integrating physical therapy into the treatment plan

Physical therapy was started five days after the injection, and carried out twice weekly

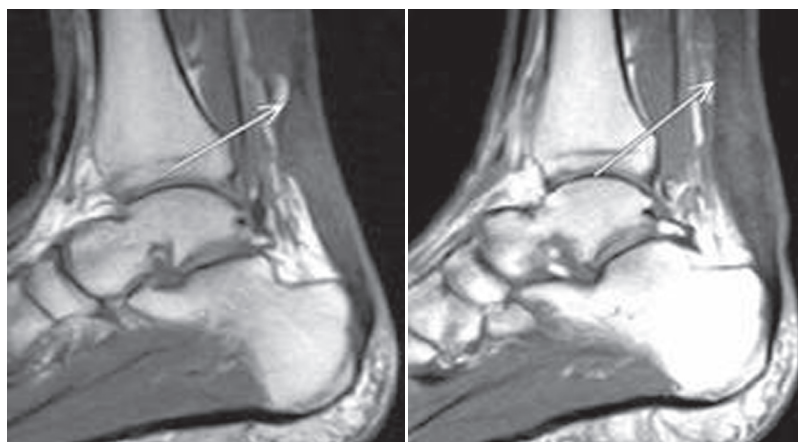


Figure 1a. Sagittal T1 images of the Achilles tendon pre and post-platelet-rich plasma (PRP) injection. The image on the left shows a tear of the Achilles tendon pre-PRP at the musculotendinous junction (arrow). The image on the right shows the intact Achilles tendon without evidence of tear at the musculotendinous junction (arrow).

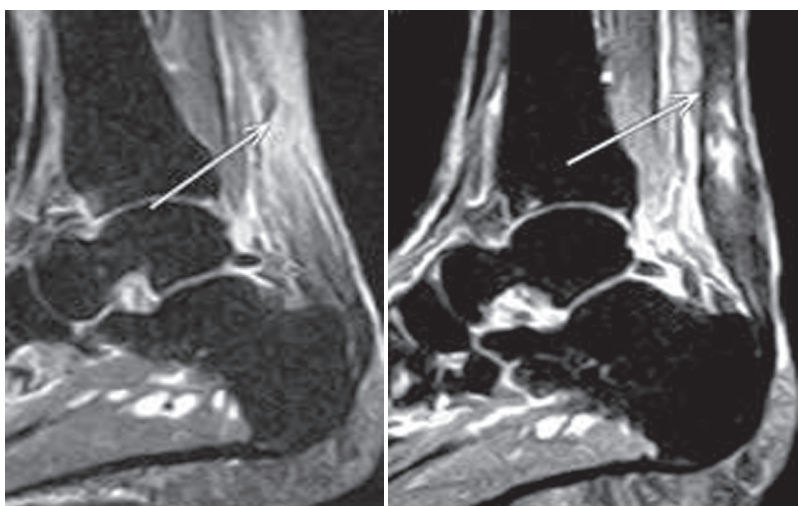


Figure 1b. STIR images of the Achilles tendon. The image on the left, which is pre-platelet-rich plasma (PRP) injection, shows a large tear with few intact posterior fibres (arrow). The image on the right is post-PRP injections, which shows a thickened Achilles tendon indicative of tendonitis without evidence of rupture (arrow).

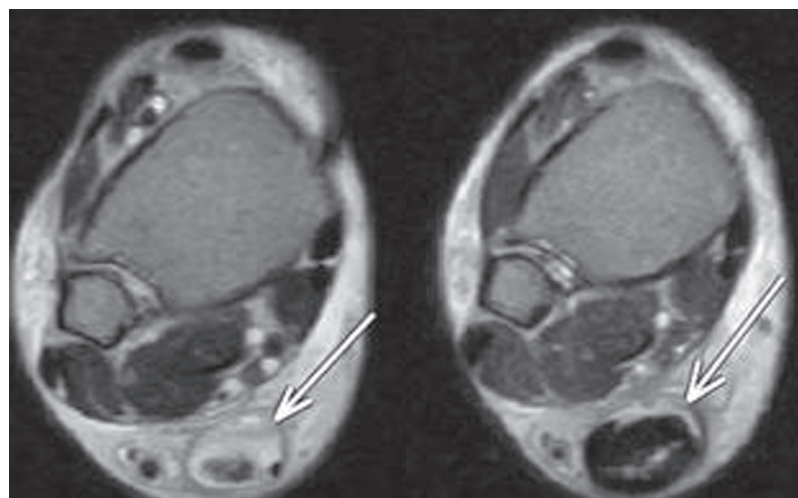
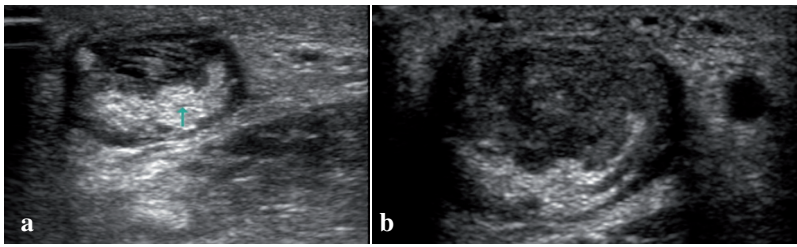


Figure 1c. T2 Axial images of the Achilles Tendon pre- and post-platelet-rich plasma (PRP) injection. The image on the left is indicative of the Achilles tendon tear (arrow), while the image on the right shows repaired Achilles tendon, which is now thickened and demonstrates fluid compatible with Achilles tendinitis (arrow).



**Figure 2a,b.** The image on the left is pre-platelet-rich plasma (PRP) injection treatment. The ultrasound image demonstrates a swollen tendon characterized by a superficial hypo/anechoic characteristic, as well as clearly defined intratendinous fluid filled transverse tearing. Focal hyperechoic area at the deep margin represents poorly organized fusiform, blunt contracted fibres in the distal segment. The image on the right is post-PRP treatment. The ultrasound image demonstrates decreased fluid filled tear lines in the superficial segment. Additionally, the fusiform non-organized hyperechoic segment is decreased in size. The overall tendon appearance is more organized, with a smaller degree of blunt contraction.

for a period of six weeks, to facilitate recovery. Prior to starting therapy the patient was instructed to weight bear as tolerated, along with discontinuing the walking boot, which was promoting biomechanical dysfunctions. Studies have shown that physical activity, versus immobilization, helps speed up the repair process (Metzl et al, 2008). Soft tissue mobilization and edema massage, along with modalities including laser, electrical stimulation and ice were performed to reduce swelling. Active treatment consisted of range of motion, stationary cycling, and lower extremity strengthening, and eccentric exercises. Eccentric exercises are thought to promote collagen fibre cross-linkage in the tendon facilitating tendon repair (Woodley et al, 2007). Studies have shown that eccentric exercise improves pain, strength and function (Andes and Murrell, 2008).

### Follow-up evaluation (6 weeks)

After PRP injection, the patient had chosen to discontinue use of his walking boot. He reported increased swelling in the affected foot since his initial evaluation and PRP treatment, which subsided significantly with physical therapy treatments. Follow-up examination at 6-weeks (following PRP injection) demonstrated mild pitting edema of the right ankle, with no tenderness to palpation. Additionally, tenderness to palpation at the Achilles tendon was absent in spite of palpable thickening. The patient displayed normal ankle range of motion and manual muscle testing with intact sensation of the right ankle. The patient continued to ambulate with an antalgic gait with persistent reduced ambulatory potential, as compared to his pre-injury status.

A diagnostic musculoskeletal ultrasound of the right Achilles tendon showed an

enlarged cross-section of the Achilles tendon that was indicative of early regeneration (Figure 2b). Focal fibrosis was present at the mid tendon region and only a small focal tear remained.

### Follow-up evaluation (24 weeks)

A follow-up MRI of the Achilles tendon revealed an intact, thickened tendon without evidence of tears at the musculotendinous junction (Figure 1a). MRI revealed T2 hyperintensity and T1 hypointensity demonstrating fluid build-up within the thickened Achilles tendon, indicative of tendonitis. The fluid in the central portion of the Achilles tendon had a craniocaudal height of 2.5 cm and an anteroposterior extent of 8 mm. Nonetheless, there was no evidence of the previously described severe Achilles tear. At this time, the patient reported full functional return of his pre-injury activity levels, including stair climbing and playing badminton.

### CONCLUSION

Repair of Achilles tendon tears provides many challenges. Surgical re-attachment of torn tendon fibres has been a common practice, but is considerably more invasive, with increased complication rates and associated expenses. Post-operative tendon healing is accomplished by several stages including inflammation, formative, and remodeling stages (Aspenberg, 2007). This process often takes a while to occur and the resulting tendon is usually weaker. One of the factors that contributes to limited tendon healing is poor vascular supply. In fact, most tears are located at the avascular calcaneal insertion (Filardo et al, 2010).

Recently several studies have shown the significance of growth factors in the reparative process of tendons. PRP contains multiple growth factors that contribute to the healing process. Vascular endothelial growth factor (VEGF) promotes angiogenesis. Platelet derived growth factor (PDGF), insulin like growth factor (IGF-1) and fibroblast growth factor (FGF), together facilitate healing and proliferation. Lastly, transforming growth factor beta (tgf-b) increases mechanical strength, as well as increasing expression of pro-collagen 1 and 3 (Molloy, 2003; Kashiwagi, 2004). A recent study demonstrated that local injection of

PRP into a partially torn Achilles tendon six days after initial injury facilitated a rapid repair of the tendon, with pain relief and return to previous activity level within two to three months of the injection (Filardo et al, 2010).

In this current case report, non-surgical, ultrasound guided injection of PRP into the Achilles tendon within one month of injury, significantly improved a 90% Achilles tendon rupture in 6 weeks, leaving only a small focal tear. At 24 weeks, the tear was completely resolved, and the patient returned to full functional activity without limitations, and without using a brace that restricted activities of daily living.

This preliminary case report supports the potential utility of PRP as a first-line treatment to repair acute Achilles tendon tears, without having to resort to surgery or undergo a prolonged rehabilitation process with activity restrictions secondary to bracing. Unfortunately, interpretation of the data in this single case report is limited. Further studies should incorporate baseline and follow-up measures, including the foot and ankle outcomes questionnaires and visual analog pain scale.

Ultimately, a large randomized multi-centered study with long term follow-up supported with serial MRI and sonographic imaging is needed before the adoption of PRP injection as a standard treatment option for acute Achilles tendon tears. While there remains optimism regarding the promise of biological based therapies, larger controlled trials are needed to determine if this particular therapy is safe and effective for the treatment of various tendon injuries for acute and chronic settings. **IJTR**

*Conflict of interest: none*

Andes BM, Murrell GAC (2008) Treatment of tendinopathy: what works, what does not, and what is on the horizon. *Clin Orthop Relat Res* **466**(7): 1539–54

Aspenberg P (2007) Stimulation of tendon repair: mechanical loading, GDFs and platelets. A mini-review. *Int Orthop* **31**(6): 783–9

Aspenberg P, Virchenko O (2004) Platelet concentrate injection improves Achilles tendon repair in rats. *Acta Orthop Scand* **75**(1): 93–9

Chang HJ, Burke AE, Glass RM (2010) JAMA patient page. Achilles tendinopathy. *JAMA* **303**(2): 188

De Vos RJ, Weir A, Van Schie HTM et al (2010) Platelet-rich plasma injection for chronic Achilles tendinopathy: a randomized controlled trial. *JAMA*

**303**(2): 144–9

Everts P, Knape J, Weirich G et al (2006) Platelet-rich plasma and platelet gel: a review. *J Extra Corpor Technol* **38**(2): 174–87

Filardo G, Lo Presti M, Kon E, Marcacci M (2010) Nonoperative biological treatment approach for partial Achilles tendon lesion. *Orthopedics* **33**(2): 120–3

James SL, Ali K, Pocock C, Robertson C, Walter J, Bell J, Connell D (2007) Ultrasound guided dry needling and autologous blood injection for patellar tendinosis. *Br J Sports Med* **41**(8): 518–21

Kashiwagi K, Mochizuki Y, Yasunaga Y, Ishida O, Deie M, Ochi M (2004) Effects of transforming growth factor-beta 1 on the early stages of healing of the Achilles tendon in a rat model. *Scand J Plast Reconstr Surg Hand Surg* **38**(4): 193–7

Leahy M (2010) PRP Effective in Treating Chronic Achilles Tendinosis. *American Academy of Orthopaedic Surgeons Now* **4**(3). Online. <http://tinyurl.com/4oooboo> (accessed 18 January 2011)

Metzl JA, Ahmad CS, Levine WN (2008) The ruptured Achilles tendon: operative and non-operative treatment options. *Curr Rev Musculoskelet Med* **1**(2): 161–4

Mishra A, Woodall Jr. J, Vieira (2009) Treatment of tendon and muscle using platelet-rich plasma. *Clin Sports Med* **28**(1): 113–25

Molloy T, Wang Y, Murrell G (2003) The roles of growth factors in tendon and ligament healing. *Sports Med* **33**(5): 381–94

Sánchez M, Anitua E, Azofra J, Andía I, Padilla S, Mujika (2007) Comparison of surgically repaired Achilles tendon tears using platelet-rich fibrin matrices. *Am J Sports Med* **35**(2): 245–51

Sampson SJ, Gerhardt M, Mandelbaum M (2008) Platelet rich plasma injection grafts for musculoskeletal injuries: a review. *Curr Rev Musculoskelet Med* **1**(3-4): 165–74

Woodley BL, NewshamWest RJ, Baxter GD (2007) Chronic tendinopathy: effectiveness of eccentric exercise. *Br J Sports Med* **41**(4): 188–98

Wolf AD, Pfleyer B (2003) Burden of major musculoskeletal conditions. *Bull World Health Organ* **81**(9): 646–56

## KEY POINTS

- Platelet-rich plasma (PCP) injection has shown promising results as an alternative to surgery.
- PRP contains a high concentration of growth factors that have been shown to be essential in the repair of tendons and ligaments.
- Achilles tendon repair surgery is more invasive, expensive and has the potential for complications, versus PRP.
- The usage of ultrasound technology for the injections allows one to localize to the site of injury.
- More studies, with larger groups of individuals need to be done in order to establish both the safety and efficacy of PRP.

## COMMENTARY

Due to the increasing number of individuals participating in physical activities, more and more musculoskeletal injuries are occurring, and tendon injuries, especially of the Achilles tendon, are one of the major concerns in sports medicine. Tissue repair in musculoskeletal lesions is often a slow, and sometimes incomplete, process. In particular, significant partial tendon ruptures seem to respond poorly to conservative measures, and do not improve with time, so surgery is most often considered the preferable treatment option for this kind of lesion. However, as correctly highlighted by the authors of this article, patients who undergo surgery have a long recovery period, with increased incidence of complications.

The search for a minimally-invasive solution to improve tendon healing is therefore highly desirable, especially in sports patients where fast recovery of full efficiency and return to competition are of primary importance.

### New biological approach

An optimal treatment should aim to restore patients to their pre-injury status in a safe, cost-effective way, and as quickly as possible.

Several studies have revealed a complex regulation of growth factors (GFs) for the normal tissue structure and the reaction to tissue damage. Therefore, their use is thought to be useful in clinical practice. Platelets contain a reservoir of GFs. In this view, the positive effects of platelet concentrate injections on tissue healing might be attributed to the higher content and secretion of GFs, which can be placed directly into the lesion site in physiological proportions. In fact, with respect to purified individual GFs or experimental associations, platelet-rich plasma (PRP) has the theoretical advantage of containing numerous bioactive molecules with a natural balance of anabolic and catabolic functions, thus potentially optimizing the tissue environment and favouring the healing process (Kon et al, 2010).

The attractive possibility to use the patients' own GFs to enhance reparative process in tissues with low healing potential, the promising preclinical studies and preliminary clinical findings

**“Tissue repair in musculoskeletal lesions is often a slow, and sometimes incomplete, process.”**

other than the safety of this treatment approach, explain its worldwide clinical application.

### Controversial preliminary findings

It is demonstrated that the healing tendon is responsive to local application of GFs and platelet concentrate injections may be useful for the treatment of tendon ruptures, as suggested by in vitro and animal studies. Nevertheless, the existing data on PRP use in clinical studies are controversial.

In particular, De Vos et al (2010) applied PRP for chronic Achilles tendinopathy, and in a randomized trial he found no difference in pain and activity improvement at 6 months' follow-up, with respect to the saline injection control. However, despite the robust scientific study design, these results do not clearly demonstrate that PRP is useless, for the reasons reported in this article. Moreover, more recently, another similar PRP application demonstrated its healing potential for the treatment of tendon lesions. In a double-blind randomized controlled trial Peerbooms et al (2010) found that one PRP injection reduced pain and increased function significantly in chronic lateral epicondylitis at 1 year follow-up, thus exceeding the effect of corticosteroid injections.

### Conclusions

Tendon healing is a complex process that involves several stages, including the inflammatory, reparative and remodeling phases. Platelets participate predominantly in the early inflammation phases, and, degranulating, produce a great number of GFs that initiate and maintain the healing process, thus PRP application should exert the greatest effect in acute injuries during the first healing phase. However, in most of the published human studies, PRP is typically injected at a point of chronic status of tendinopathy. This article is one of the first reports documenting the usage of PRP as a first line treatment in an acute setting to facilitate repair for a severe traumatic Achilles tendon tear, provid-

ing documented MRI and sonographic evidence of healing. Moreover, with respect to the previously published successful treatment of an acute partial rupture of the Achilles tendon in an athlete (Filardo et al, 2010), this report documents the efficacy of PRP in a 71-year-old male, thus suggesting that even older patients may benefit and respond to platelet GFs' stimulus.

Finally, the importance of the associated rehabilitation has to be underlined. As hypothesized by Aspenberg and Virchenko (2004), there is an interplay between early regeneration and mechanical stimulation: platelet-derived GFs may influence the initial inflammatory phases of tendon healing, making it more receptive to mechanical loading, and this has to be considered by all clinicians who decide to apply this procedure.

Preliminary findings such as this case report suggest that PRP may represent a promising, less invasive, therapeutic option for the treatment of partial tendon tears for patients otherwise candidates for surgery. However, further studies are necessary to verify the potential of this procedure before there is a wide clinical application.

Kon E, Filardo G, Di Martino A, Marcacci M (2010) Platelet-rich plasma (PRP) to treat sports injuries: evidence to support its use. *Knee Surg Sports Traumatol Arthrosc* [Epub ahead of print]

De Vos RJ, Weir A, van Schie HT et al (2010) Platelet-rich plasma injection for chronic Achilles tendinopathy: a randomized controlled trial. *JAMA* **303**(2): 144–9

Peerbooms JC, Sluimer J, Bruijn DJ, Gosens T (2010) Positive effect of an autologous platelet concentrate in lateral epicondylitis in a double-blind randomized controlled trial: platelet-rich plasma versus corticosteroid injection with a 1-year follow-up. *Am J Sports Med* **38**(2): 255–62

Filardo G, Presti ML, Kon E, Marcacci M (2010) Nonoperative biological treatment approach for partial Achilles tendon lesion. *Orthopedics* **33**(2): 120–3

Aspenberg P, Virchenko O (2004) Platelet concentrate injection improves Achilles tendon repair in rats. *Acta Orthop Scand* **75**(1): 93–9

**Giuseppe Filardo, MD**  
Biomechanics Laboratory  
Rizzoli Orthopaedic Institute  
Bologna, Italy  
[g.filardo@biomec.ior.it](mailto:g.filardo@biomec.ior.it)