

Accuracy of Needle Placement into the Intra-Articular Space of the Knee

BY DOUGLAS W. JACKSON, MD, NICHOLAS A. EVANS, MD, AND BRADLEY M. THOMAS, MD

Investigation performed at Southern California Center for Sports Medicine, Long Beach, California

Background: To achieve their potential therapeutic benefit, hyaluronic acid derivatives should be injected directly into the knee joint space and not into the anterior fat pad or the subsynovial tissues. In the absence of a knee effusion, reproducible needle placement into the intra-articular space presents a challenge to the clinician.

Methods: The accuracy of needle placement was assessed in a prospective series of 240 consecutive injections in patients without clinical knee effusion. The injections were performed by one orthopaedic surgeon using a 2.0-in (5.1-cm) 21-gauge needle through three commonly employed knee joint portals: anteromedial, anterolateral, and lateral midpatellar. Accuracy rates for needle placement were confirmed with fluoroscopic imaging to document the dispersion pattern of injected contrast material.

Results: Of eighty injections performed through an anterolateral portal, fifty-seven were confirmed to have been placed in the intra-articular space on the first attempt (an accuracy rate of 71%). Sixty of eighty injections performed through an anteromedial approach were intra-articular on the first attempt (75% accuracy rate), as were seventy-four of eighty injections performed through a lateral midpatellar portal (93% accuracy rate).

Conclusions: Using real-time fluoroscopic imaging with contrast material, we demonstrated the difficulty of accurately placing a needle into the intra-articular space of the knee when an effusion is not present. This study revealed that a lateral midpatellar injection (an injection into the patellofemoral joint) was intra-articular 93% of the time and was more accurate than injections performed by the same orthopaedic surgeon using either of the other two portals. This study highlights the need for clinicians to refine injection techniques for delivering intra-articular therapeutic substances that are intended to coat the articular surfaces of the knee joint.

Osteoarthritis is one of the most common and costly chronic medical conditions¹. At present, there is no evidence that medical intervention alters the rate of deterioration of the articular surfaces of an affected joint. Most current therapies are directed toward minimizing pain and swelling, maintaining joint mobility, and reducing associated disability.

In osteoarthritis, there is a reduction in the elastoviscosity of the synovial fluid secondary to a decrease in the molecular weight and concentration of hyaluronic acid. Viscosupplementation is a therapeutic technique that addresses the decrease in synovial viscosity with the injection of exogenous high-molecular-weight hyaluronan molecules^{2,3}. Viscosupplementation was initially used to treat post-traumatic osteoarthritis in racehorses and was later used to treat knee arthritis in humans in the early 1970s. In 1997, hyaluronan was approved by the Food and Drug Administration as a fluid prosthesis—that is, an intra-articular substance to coat the articular surfaces. Two brands of viscosupplements, both of which are purified from chicken combs, are commercially available in the United States. Sodium hyaluronate (Hyalgan; Sanofi Pharma-

ceuticals, New York, NY) has a molecular weight of 500,000 to 730,000 Da and is administered in one injection per week for five weeks. Hylan G-F 20 (Synvisc; distributed by Wyeth Laboratories, Wyeth-Ayerst, Philadelphia, Pennsylvania) contains cross-linked hyaluronate, increasing its molecular weight to 6 million Da, and is administered in one injection per week for three weeks.

The mechanism by which viscosupplementation alleviates arthritic knee pain has been related to the biomechanical effect of improving elastoviscosity, which creates better joint lubrication and shock absorption. Studies have indicated that exogenous hyaluronan stimulates endogenous production of hyaluronate by synoviocytes, thereby “normalizing” the viscosity of joint fluid in patients with osteoarthritis^{4,5}. It has been suggested that hyaluronan supplementation has a direct anti-inflammatory effect on synoviocytes by inhibiting release of arachidonic acid or by blocking production of prostaglandin- E_2 ^{6,7}. Hyaluronan may also inhibit damage mediated by oxygen free radicals and phagocytosis^{8,9}. In addition, hyaluronate may exert a direct analgesic effect on intra-articular nociceptors, helping to relieve the symptoms of osteoarthritis^{10,11}.

Several human clinical trials have shown a single course of three weekly injections of hyaluronan to be more effective than saline solution and equivalent or better than nonsteroidal anti-inflammatory therapy combined with arthrocentesis¹²⁻¹⁵. In order to achieve the maximal potential therapeutic benefit, hyaluronan-based preparations should be delivered directly into the intra-articular space and not into the anterior fat pad or the subsynovial tissue layers¹⁶.

Few studies have evaluated the accuracy of needle placement into the intra-articular space of the knee joint in the absence of an effusion¹⁷⁻¹⁹. Needle placement is easily confirmed when an effusion is present. During joint aspiration for effusion, the return of synovial fluid documents intra-articular placement of the needle. Manufacturers of hyaluronan-based preparations have recommended that the injection be placed into a "dry" joint. In the absence of an effusion, needle placement requires the use of anatomic landmarks and tactile feedback to help the physician to position the needle. Several anecdotal, and a few published, methods have been proposed to increase the accuracy of intra-articular placement of the needle in the absence of an effusion. These include preinjection of air or saline solution, aspiration of moisture into the barrel of the syringe, minimal retraction of the needle tip after palpation of an articular cartilage or bone surface, or fluoroscopic injection of contrast material¹⁷⁻²⁰.

The purpose of this study was to evaluate the accuracy rate of one orthopaedic surgeon using anteromedial, anterolateral, and lateral midpatellar approaches for intra-articular placement of a needle into the knee joint space in a clinic setting.

Materials and Methods

The accuracy of needle placement was assessed prospectively in a consecutive series of patients who were given Synvisc injections for the treatment of symptomatic degenerative joint

disease of the knee. The treatment involved three intra-articular injections of Synvisc into the affected knee with weekly intervals between the injections, according to the manufacturer's recommended protocol. Patients with clinically detectable knee joint effusion were excluded from the study. The injections were performed in an office setting by one orthopaedic surgeon (D.W.J.) who specialized in knee joint disorders.

Needle placement was determined with an in-office portable fluoroscopic unit (Premier; Fluoroscan Imaging Systems, Northbrook, Illinois) to demonstrate the dispersion pattern of injected contrast material. This machine emits a low radiation dose and a tightly collimated beam, reducing radiation scatter to a low level that does not require lead-shielding.

A three-way stopcock was utilized for the study injections (Fig. 1). Synvisc was placed in the syringe opposite to the needle, and radiopaque Isovue-300 contrast solution (Bracco Diagnostics, Princeton, New Jersey) was placed in the syringe at 90° to the needle. This allowed the passage of both the radiopaque solution and the Synvisc material through the same needle with only one needle placement. The stopcock was initially opened to the syringe containing the Isovue-300, and 0.5 mL of this contrast solution was injected into the joint. A fluoroscopic image was made to evaluate dispersion of the contrast material. If intra-articular placement was confirmed, the stopcock was opened to the other syringe for injection of the Synvisc. If the initial needle placement did not result in dispersion of the injected contrast material within the knee joint cavity, the needle was repositioned until intra-articular placement was confirmed fluoroscopically with an additional injection of contrast material. Inaccurate initial placement of the needle requiring repositioning of the needle was considered a failure for the purpose of this study.

We compared the accuracy of injections through three commonly used sites for intra-articular injections into the knee joint: anterolateral, anteromedial, and lateral midpatellar

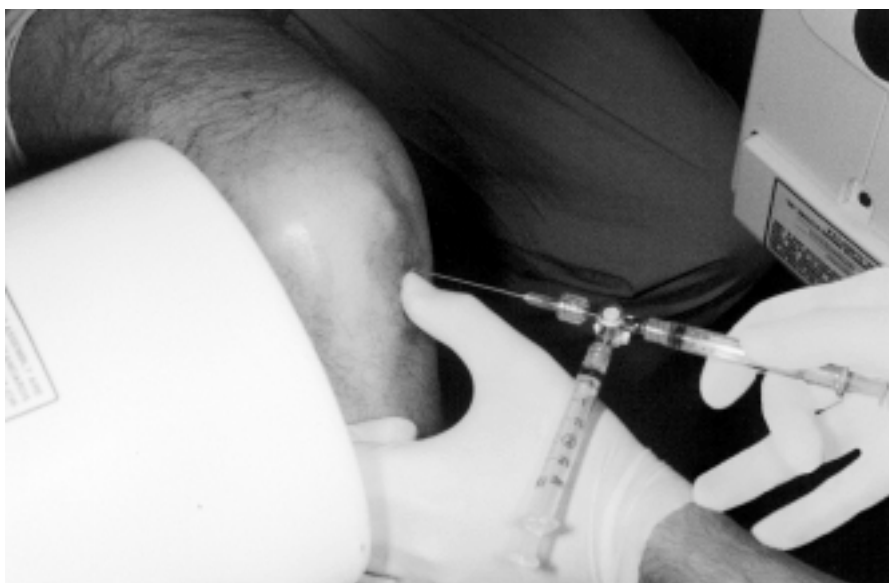

Fig. 1
Three-way stopcock used for needle placement with the syringes containing Synvisc and contrast medium attached. The knee, which was prepared by the physician prior to the injection, is flexed 90° with the leg hanging free over the side of the examination table. The mini-c-arm of the Fluoroscan unit is in position.

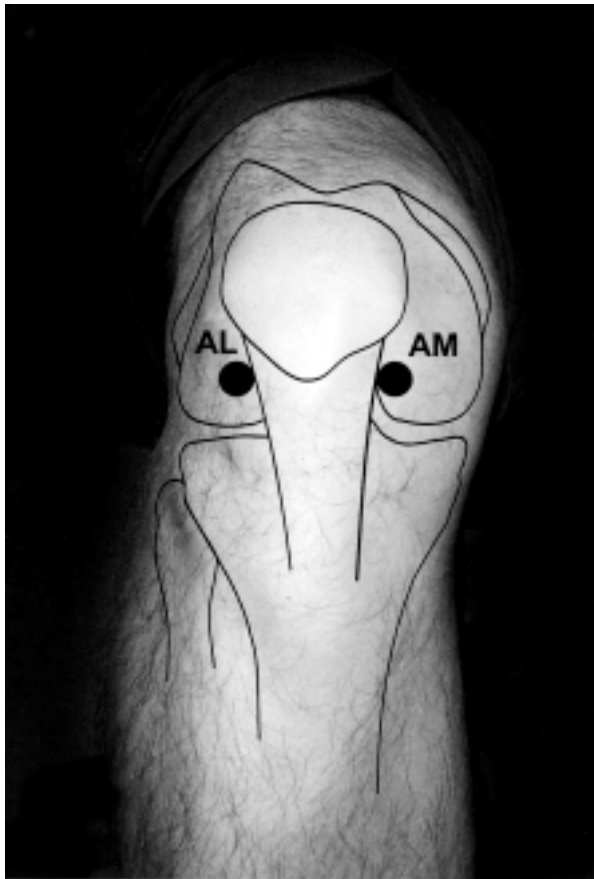


Fig. 2-A
Schematic representation of the anterolateral (AL) and anteromedial (AM) portals.

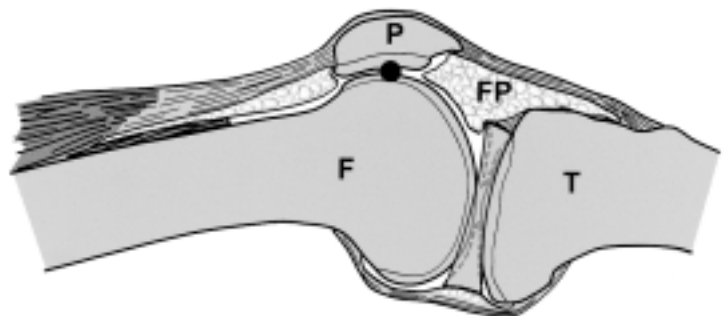
portals. The anterolateral and anteromedial injections were performed with the patient sitting and the affected leg hanging over the side of the examination table with the knee flexed to approximately 90°. The patient's foot was allowed to hang freely without contact with the floor or a stool. On the basis of careful palpation of anatomical landmarks, the injection site was selected inferior to the patella, one finger-breadth proximal to the tibial joint surface, and either medial or lateral to the patellar tendon (Fig. 2-A). The needle was directed obliquely toward the intercondylar notch. The

lateral midpatellar injections were performed with the lower limb extended on the examination table. The patella was manually everted and moved laterally by the physician's free hand. The needle was advanced transversely between the articular surfaces of the patellofemoral joint at the midpoint of the patella (Fig. 2-B).

Prior to needle placement, the mini-c-arm of the Fluoroscanner unit was positioned to obtain an initial lateral image to center the knee on the screen. The skin around the injection site was prepared with Betadine (povidone-iodine), and the area was partially anesthetized by spraying ethyl chloride onto the skin. Surgical gloves were worn by the physician during the injections. The needle was positioned in what was thought to be the desired location, and 0.5 mL of contrast material was injected into the knee. A second lateral image was obtained to document dispersion of the contrast material. With correct needle placement, the contrast material dispersed freely within the joint and was seen to "coat" the articular surface (Fig. 3). Dispersion of the contrast material was confirmed with a repeat Fluoroscanner image obtained after the knee was cycled five times through a range of motion. When the needle was positioned incorrectly, the contrast material pooled as a bolus in either the fat pad or the subsynovial tissues (Fig. 4). As mentioned, incorrect initial placement of the needle was considered a failure for the purpose of this study. To ensure accurate delivery of the Synvisc, the needle was repositioned if necessary until an intra-articular placement was confirmed with a repeat injection of contrast solution. The stopcock was then opened to the syringe containing Synvisc, which was injected into the intra-articular space.

A 2-in (5.1-cm) 21-gauge needle was attached to the stopcock in this study. We had been using a 1.5-in (3.8-cm) 22-gauge needle for intra-articular corticosteroid injections in our office. However, during an initial pilot study involving thirteen injections with a 1.5-in needle through an anterolateral portal into the knee joint, nine injections were placed into the infrapatellar fat pad. In order to estimate the needle length required to reach the articular surface, we evaluated the size of the fat pad using magnetic resonance imaging scans of the knee joints of five volunteers (age range, thirty-three to fifty-five years; female-to-male ratio, 3:2). The distance measured from the skin edge to the articular surface of the femoral condyle ranged from 4.5 to 5.5 cm (1.8 to 2.2 in). On the basis

Fig. 2-B
Diagram showing the lateral midpatellar portal. P = patella, F = femur, T = tibia, and FP = fat pad.



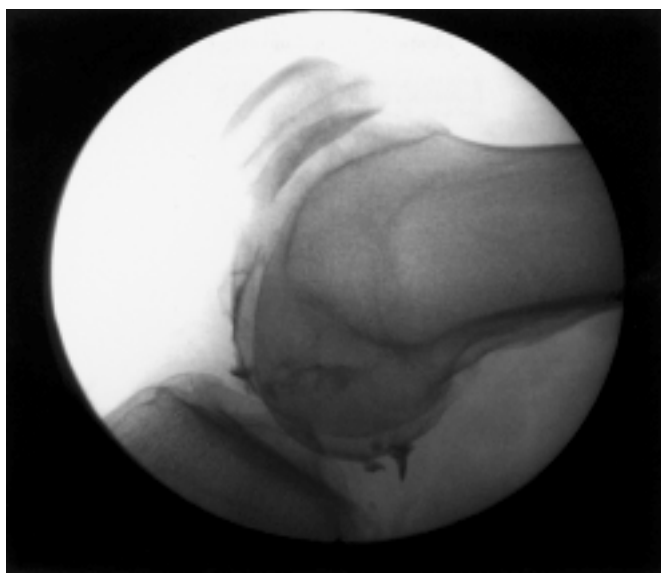


Fig. 3

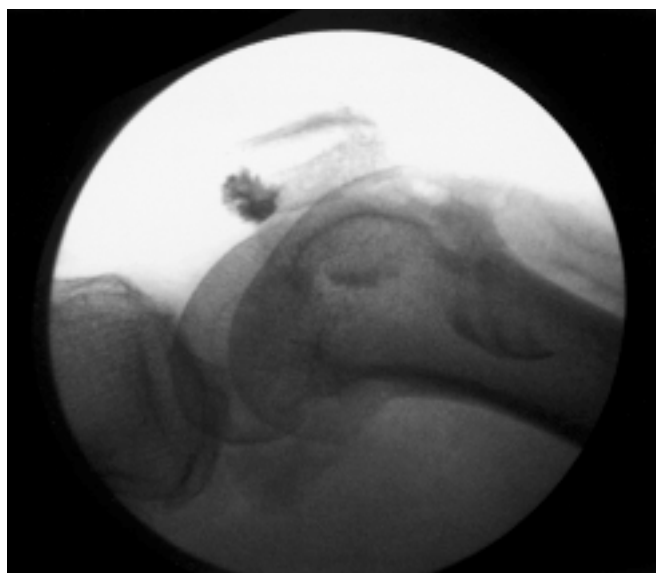

Fig. 4

Fig. 3 Fluoroscan image demonstrating accurate intra-articular placement of the needle. The injected contrast medium “coats” the articular surface of the femoral condyle and accumulates in the posterior compartment of the knee joint. **Fig. 4** Fluoroscan image showing inaccurate, extra-articular placement of the needle, with the injected contrast medium contained in the fat pad.

of these preliminary data, we selected a needle length of 2 in for the study, predicting that the additional 0.5-in (1.3-cm) length would help the needle to clear the intra-articular fat pad and reach the intra-articular space.

Eighty patients without clinical knee effusion were included in this prospective study. The age range of the patients was twenty-eight to eighty-five years. There were forty-two female patients and thirty-eight male patients. Initial needle placement was documented for 240 consecutive injections prior to injection of the Synvisc for the treatment of symptomatic degenerative joint disease of the knee. Eighty injections were placed into each of the three study portals by one orthopaedic surgeon using a 2-in 21-gauge needle.

Statistical Analysis

The data were organized into contingency tables, and statistical analysis was performed with use of the Fisher exact test (two-sided, 95% confidence interval). Comparisons were made between the actual result and the expected result (i.e., a

100% rate of intra-articular placement) and among the portals (anterolateral, anteromedial, and lateral midpatellar). An alpha level of <0.05 was considered significant.

Results

A summary of the accuracy rates of the injections is presented in Table I.

The actual rate of accurate intra-articular needle placement was significantly lower than the expected rate (100%) when the anterolateral portal ($p < 0.0001$) or anteromedial portal ($p < 0.0001$) was used. There was no significant difference ($p > 0.05$) between the expected rate (100%) and the actual rate (93%) of accurate needle placement through the lateral midpatellar portal. There was also no significant difference ($p > 0.05$) between the results obtained with placement through the anteromedial and anterolateral portals, but the accuracy obtained with use of the lateral midpatellar portal was significantly greater than that obtained with use of either the anteromedial ($p < 0.01$) or anterolateral ($p < 0.001$) portal.

TABLE I Rates of Accuracy of Intra-Articular Injections

Portal	Total No. of Injections	Placement of Needle (no. of injections)		Accuracy Rate
		Extra-Articular	Intra-Articular	
Anterolateral	80	23	57	71%
Anteromedial	80	20	60	75%
Lateral midpatellar	80	6	74	93%

Discussion

A review of the literature revealed few studies on the accuracy of needle placement into the intra-articular space of the knee in the absence of a joint effusion. Jones et al.¹⁷ used a single radiograph to evaluate the accuracy of injections of a mixture of depomethylprednisolone and radiographic contrast medium by five rheumatologists with differing seniority. They reported that thirty-nine (66%) of fifty-nine knee joint injections were intra-articular according to their criteria and almost one-third were extra-articular. The authors did not describe their injection method or document whether an effusion was present in the knee joints being injected. Interestingly, the response to steroid therapy was similar regardless of whether the injection was intra-articular or extra-articular. In view of the poor accuracy rate, the authors recommended that injection techniques be refined.

Bliddal¹⁸ evaluated the accuracy of superolateral steroid injections, which he verified with mini-air arthrography. He reported that fifty-one of fifty-six injections were intra-articular. Waddell et al.¹⁹ used real-time Fluoroscan imaging to assess the accuracy of needle placement through an anterolateral portal with the knee flexed between 30° and 40°. Injections were performed in twenty normal knees of eleven healthy volunteers, and the authors reported an accuracy rate of 100%. This study may have underestimated the potential difficulties encountered when performing injections, without the benefit of fluoroscopic confirmation, in abnormal knees of patients with osteoarthritis and obesity.

We evaluated the accuracy of needle placement in eighty patients undergoing treatment for symptomatic degenerative joint disease. The sample included obese patients and patients whose knee joints were deformed by the degenerative process. It is important to note that establishing anatomical landmarks about the knee is more difficult in obese patients. The large quantity of subcutaneous fat also increases the distance between the skin and the joint space.

We compared the accuracy rates of needle placement, by one physician, into three commonly used knee-injection portals. Injection through the lateral midpatellar approach had an accuracy of 93%. When this route is used, the needle passes through a minimal amount of soft tissue to reach the intra-articular space. It is important to ensure that the needle is directed parallel to the everted articular facet of the patella and

that the needle does not deviate more than 15° to 20° from the midpatellar transverse plane.

Several observations made during this study may be useful to the clinician. First, the small amount (2 mL) of viscous hyaluronan and the resistance to its flow in the needle made it difficult for the clinician to feel whether the dose of Synvisc was passing into soft tissue or the joint space. Second, it is our impression that incorrect placement of a soft-tissue injection causes more discomfort to the patient during and after the procedure. When patients mentioned the sensation of pain during the injection of a small volume (0.5 mL) of contrast material, fluoroscopy frequently demonstrated a bolus of contrast medium accumulated within the extra-articular soft tissues. Third, it is a concern that painful injections are associated with extra-articular needle placement and may be linked to a higher incidence of adverse reactions. This was not established by our study, as the needle was repositioned and then confirmed to be intra-articular before the physician proceeded with the Synvisc injection. Finally, once the instantaneous discomfort of needle placement has subsided, the injection of hyaluronan should not be painful.

In conclusion, future study is needed to develop a reproducible and accurate method of therapeutic delivery into the joint without the need for fluoroscopic confirmation. Until then, we recommend using the lateral midpatellar portal with the knee extended as it is the most accurate approach for intra-articular needle placement in a knee with no effusion. ■

Douglas W. Jackson, MD

Nicholas A. Evans, MD

Bradley M. Thomas, MD

Southern California Center for Sports Medicine, 2760 Atlantic Avenue, Long Beach, CA 90806. E-mail address for D.W. Jackson:

simori@aol.com

In support of their research or preparation of this manuscript, one or more of the authors received grants or outside funding from Wyeth-Ayerst. None of the authors received payments or other benefits or a commitment or agreement to provide such benefits from a commercial entity. A commercial entity (Wyeth-Ayerst) paid or directed, or agreed to pay or direct, benefits to a research fund, foundation, educational institution, or other charitable or nonprofit organization with which the authors are affiliated or associated.

References

1. Jackson DW, Simon TM, Aberman HM. Symptomatic articular cartilage degeneration: the impact in the new millennium. *Clin Orthop*. 2001;391 Suppl:S14-25.
2. Balazs EA. The physical properties of synovial fluid and the special role of hyaluronic acid. In: Helfet AJ, editor. *Disorders of the knee*. 2nd ed. Philadelphia: Lippincott; 1982. p 61-74.
3. Balazs EA, Denlinger JL. Viscosupplementation: a new concept in the treatment of osteoarthritis. *J Rheumatol Suppl*. 1993;39:3-9.
4. Smith MM, Ghosh P. The synthesis of hyaluronic acid by human synovial fibroblasts is influenced by the nature of the hyaluronate in the extracellular environment. *Rheumatol Int*. 1987;7:113-22.
5. Altman RD, Moskowitz R. Intraarticular sodium hyaluronate (Hyalgan) in the treatment of patients with osteoarthritis of the knee: a randomized clinical trial. Hyalgan Study Group. *J Rheumatol*. 1998;25:2203-12.
6. Pelletier JP, Martel-Pelletier J. The pathophysiology of osteoarthritis and the implication of the use of hyaluronan and hylan as therapeutic agents in viscosupplementation. *J Rheumatol Suppl*. 1993;39:19-24.
7. Tobetto K, Yasui T, Ando T, Hayaishi M, Motohashi N, Shinogi M, Mori I. Inhibitory effects of hyaluronan on [14C]arachidonic acid release from labeled human synovial fibroblasts. *Jpn J Pharmacol*. 1992;60:79-84.
8. Forrester JV, Balazs EA. Inhibition of phagocytosis by high molecular weight hyaluronate. *Immunology*. 1980;40:435-46.
9. Presti D, Scott JE. Hyaluronan-mediated protective effect against cell damage caused by enzymatically produced hydroxyl (OH·) radicals is dependent on hyaluronan molecular mass. *Cell Biochem Funct*. 1994; 12:281-8.

10. **Ghosh P.** The role of hyaluronic acid (hyaluronan) in health and disease: interactions with cells, cartilage and components of synovial fluid. *Clin Exp Rheumatol.* 1994;12:75-82.
11. **Pozo MA, Balazs EA, Belmonte C.** Reduction of sensory responses to passive movements of inflamed knee joints by hylan, a hyaluronan derivative. *Exp Brain Res.* 1997;116:3-9.
12. **Adams ME.** An analysis of clinical studies of the use of crosslinked hyaluronan, hylan, in the treatment of osteoarthritis. *J Rheumatol Suppl.* 1993;39:16-8.
13. **Adams ME, Atkinson MH, Lussier AJ, Schulz JI, Siminovitch KA, Wade JP, Zummer M.** The role of viscosupplementation with hylan G-F 20 (Synvisc) in the treatment of osteoarthritis of the knee: a Canadian multicenter trial comparing hylan G-F 20 alone, hylan G-F 20 with non-steroidal anti-inflammatory drugs (NSAIDs) and NSAIDs alone. *Osteoarthritis Cartilage.* 1995;3:213-25.
14. **Wobig M, Dickhut A, Maier R, Velter G.** Viscosupplementation with hylan G-F 20: a 26-week controlled trial of efficacy and safety in the osteoarthritic knee. *Clin Ther.* 1998;20:410-23.
15. **Scale D, Wobig M, Wolpert W.** Viscosupplementation of osteoarthritic knees with hylan: A treatment schedule study. *Curr Ther Res.* 1994; 55:220-32.
16. **Lussier A, Cividino AA, McFarlane CA, Olszynski WP, Potashner WJ, De Medicis R.** Viscosupplementation with hylan for the treatment of osteoarthritis: findings from clinical practice in Canada. *J Rheumatol.* 1996; 23:1579-85.
17. **Jones A, Regan M, Ledingham J, Patrick M, Manhire A, Doherty M.** Importance of placement of intra-articular steroid injections. *BMJ.* 1993; 307:1329-30.
18. **Bliddal H.** Placement of intra-articular injections verified by mini-air arthrography. *Ann Rheum Dis.* 1999;58:641-3.
19. **Waddell D, Estey D, Bricker DC, Marsala A.** Viscosupplementation under fluoroscopic control. *Am J Med Sports.* 2001;3:237-41.
20. **Roberts WO.** Knee aspiration and injection. *Phys Sports Med.* 1998;26:93-4.

SMITH & NEPHEW, INC. IS PROVIDING THIS PUBLISHED ARTICLE FOR YOUR INFORMATION AND CONVENIENCE. THE VIEWS EXPRESSED THEREIN ARE THOSE OF THE AUTHOR OF THE ARTICLE AND ARE NOT NECESSARILY THOSE OF SMITH & NEPHEW, INC. WE WELCOME YOUR COMMENTS AND VIEWS ON THE MATTERS DISCUSSED THEREIN.

7198-1084